

# **Efficacy and Safety of Treatment with a Topical Preparation Containing Phytic Acid and L-Ascorbic Acid for Skin Pigmentation in Asians**

**Mayumi Tosa, M.D., The Mayumi Clinic**



## **Melaclear on Asian skin type**

---

### **INTRODUCTION**

In the treatment of skin pigmentation, drugs such as hydroquinone, retinoids, AHA and vitamin C are commonly prescribed for patients of Asian races as well. Particularly, development of pigmentation due to prolonged use of hydroquinone and serious reddening of the skin associated with the use of high-concentration retinoids are encountered, hence requiring control with meticulous care. Vitamin-C being a representative tyrosinase inhibitor has become applicable in the treatment of skin pigmentation because of its recently proven ability to block the four different steps during melanin synthesis via synergism with the other agents.

### **OBJECTIVES**

This report describes clinical experience with a new drug containing phytic acid and L-ascorbic acid in the treatment of patients with skin pigmentation.

### **PATIENTS AND METHODS**

The study population comprised 19 patients with pigmentary disorders of the skin (18 women and 1 man, ranging in age from 30 to 56 years) whose Fitzpatrick skin types were III to IV

The drug used in the study contained the following ingredients: 2% phytic acid, 10% L-ascorbic acid, Tea Sinensis, Vitis extract, Vinifera extract, glycerin, alcohol, ethoxy diglycol, and Aqua.

Each patient received topical application of the drug at this clinic at three weekly visits, and used a home-care preparation with the same ingredients twice daily for a period of three months after the first visit.

Pigmented lesions subject to the study treatment were recorded with a digital camera and by UV photographs prior to and after the treatment, and thereby the therapeutic response was evaluated along with interview outcome scoring as to safety and efficacy.

## **Melaclear on Asian skin type**

---

### **RESULTS**

As for safety, there was only one patient who experienced reddening at the site at 2 months of treatment, leading to discontinuation of the study topical medication. The remaining 18 patients were able to continue the study topical medication during the 3-month period without experiencing pruritus or reddening at all. As for efficacy, the therapeutic response evaluation showed alleviation of pigmentation in 14 patients, with realization of anti-aging effects such as contraction of skin pores and liveliness of the skin in 13 patients.

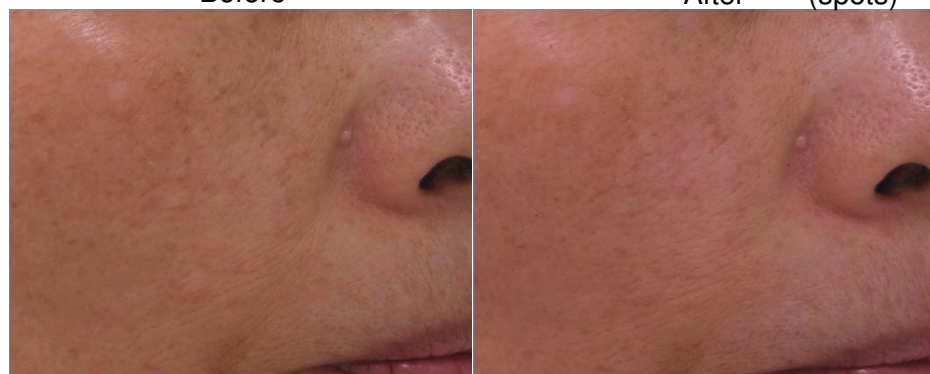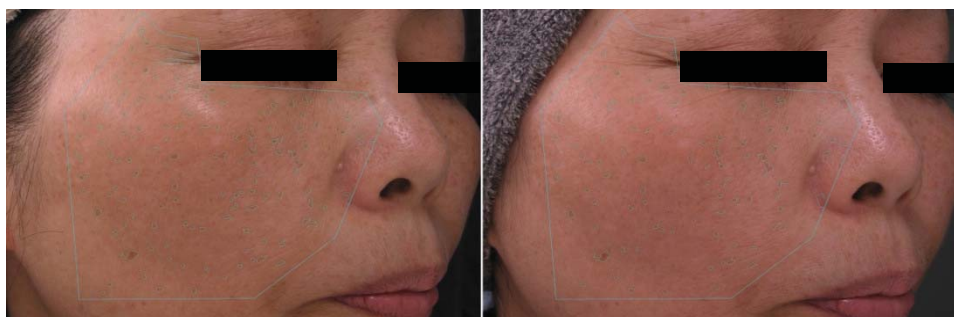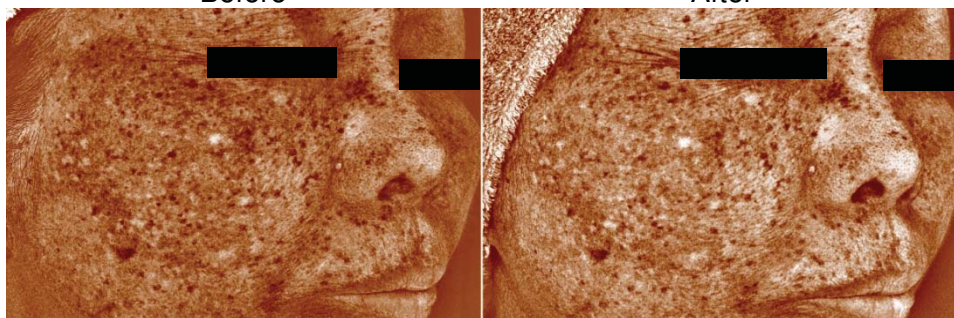
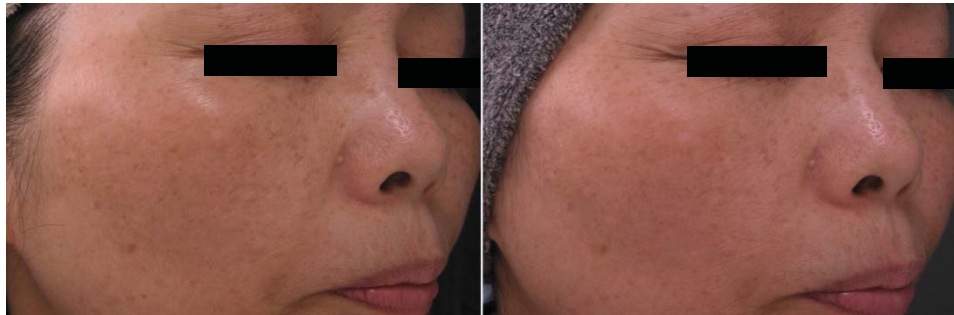### **SUMMARY AND CONCLUSION**

Whilst aggressive treatments to enhance efficacy in Asians always require attentiveness to the potential risk of complications, the combined topical formulation of phytic acid and L-ascorbic acid has proven to be safe and effective in the treatment of skin pigmentation. However, further investigation in a greater number of patients is yet to be pursued and the present results seem to indicate usefulness of the combined preparation as an anti-aging dermatologic therapy.

## Melaclear on Asian skin type

### Case 1: a 58-year-old woman treated for anti-aging purpose (treatment of skin mottles and wrinkles)

Melasma and senile pigmented spots were noted bilaterally before treatment. UV photographs taken after treatment revealed overall improvement. In particular, melasma improved remarkably.



Before [www.auriga-int.com](http://www.auriga-int.com) After

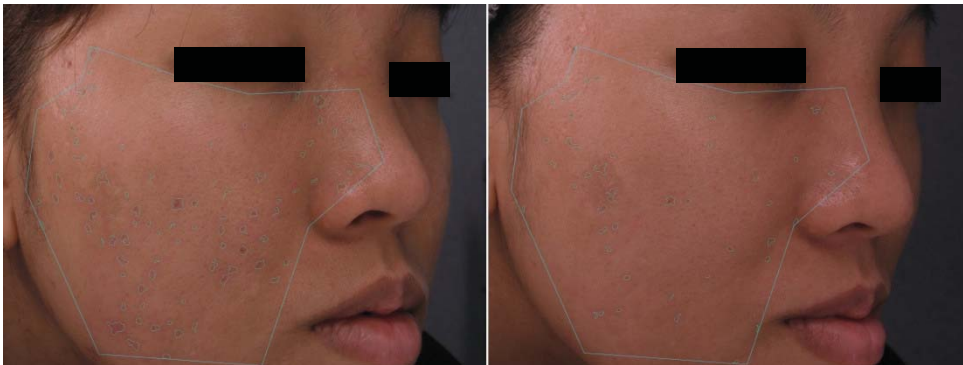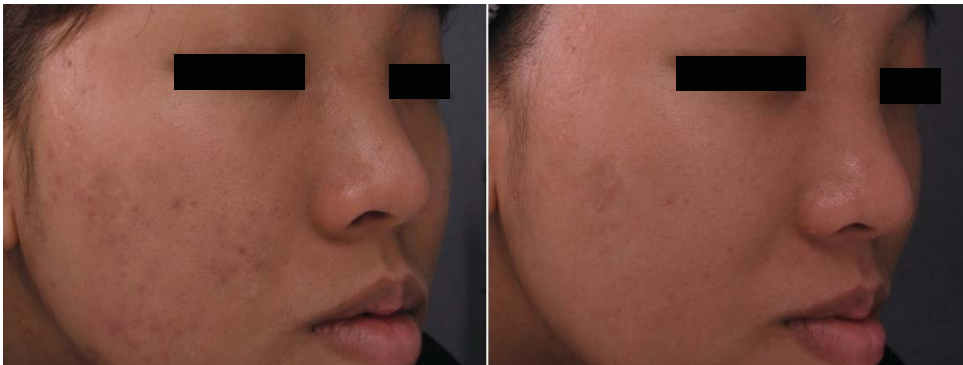---

## Melaclear on Asian skin type

---

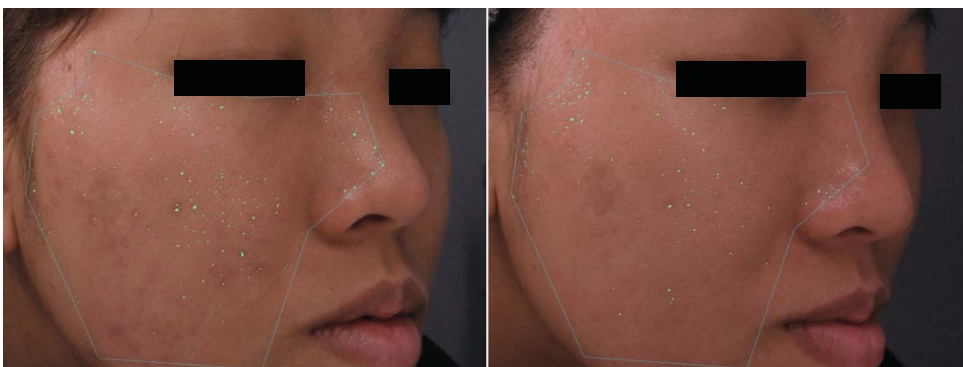### Case 2: a 30-year-old woman; treatment of acnes, acne scars, and enlarged skin pores

After treatment, reddish acne scars and skin pigmentation improved. The photograph of pores revealed pore-size reduction.



Before

After (spots)



Before

After (pores)

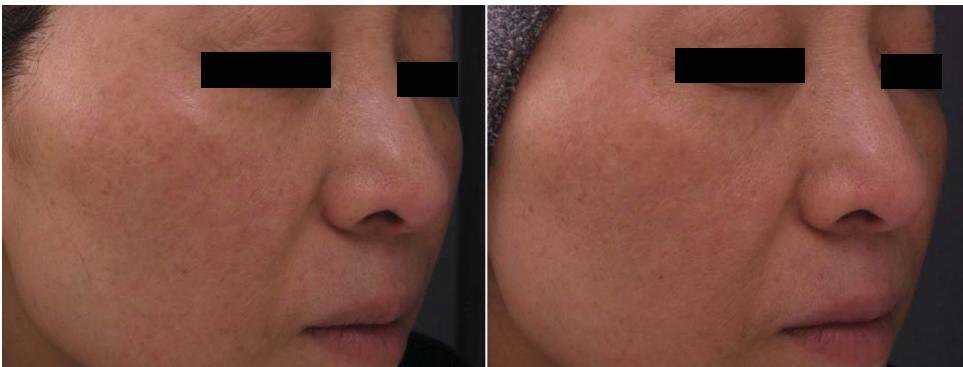---

## Melaclear on Asian skin type

---

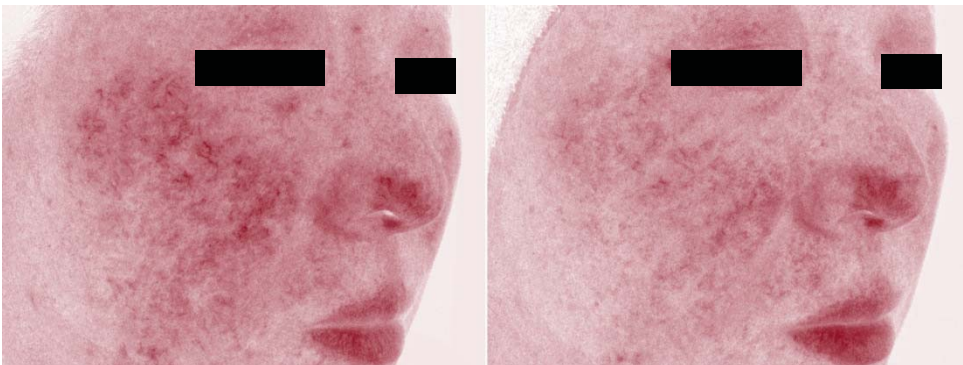
### Case 3: a 52-year-old woman treated for anti-aging purpose (treatment of wrinkles and reddish face)

Reddish face, which troubled her for 10 years, improved after treatment. The photograph of red spots revealed decrease in the number of capillary vessels in the area.



Before

After



Before

After (reddish)

# **Efficacy and tolerance of MelaClear Serum in the treatment of hyperpigmentation**

**Dr. Nikolova and Kazandjieva Medical University , Sofia, 2007**



## **Melaclear Efficacy and tolerance**

---

### **INTRODUCTION**

Increased production and accumulation of melanins characterize a large number of skin diseases, which include hyperpigmentation such as melasma, lentiginos, freckles and photoallergic reactions. Epidermal and dermal hyperpigmentation can be dependent on either increased number of melanocytes or activity of melanogenic enzymes. Ultraviolet light, chronic inflammation and abnormal  $\alpha$ -melanocyte stimulating hormone release, are triggering factors for these disorders. As a result of their prevalent localization, acquired hyperpigmentation have a psychosocial and cosmetic relevance. Since many years, a lot of efforts have been put to develop an ideal depigmenting agent who should be rapid, potent, safe. Moreover, he should carry no short-or long-term side effect and lead to a permanent removal of undesired pigment. Phytic Acid and L-Ascorbic Acid are depigmenting agents that have been classified according to their reported mechanisms of interference with melanin synthesis and deposition. These compounds are active during the melanin synthesis phase.

### **OBJECTIVES**

The aim of the study was to evaluate the effectiveness of Melaclear serum. The primary objective was the evaluation of the effect on skin pigmentation: both the area and the intensity of the pigmentary zone were investigated. The secondary objectives were the assessment of the tolerance during the treatment course.

### **PATIENTS AND METHODS**

20 patients with diagnosed hyperpigmentation (lentiginos, melasma,...) following an overexposure to the sun were enrolled. Patients were followed during a period of 3 months and evaluations were performed at discharge and after 1, 2, 3 months. Standard photographs were taken at each visit. The regression of the pigmentary areas was quantified with a graduated scale, a four-point scale (0 = worsening, 2 = lack of efficacy, 3 = good response, 4 = very good response).

The evaluation of the tolerance and the modifications of skin structures were also performed by the physicians.

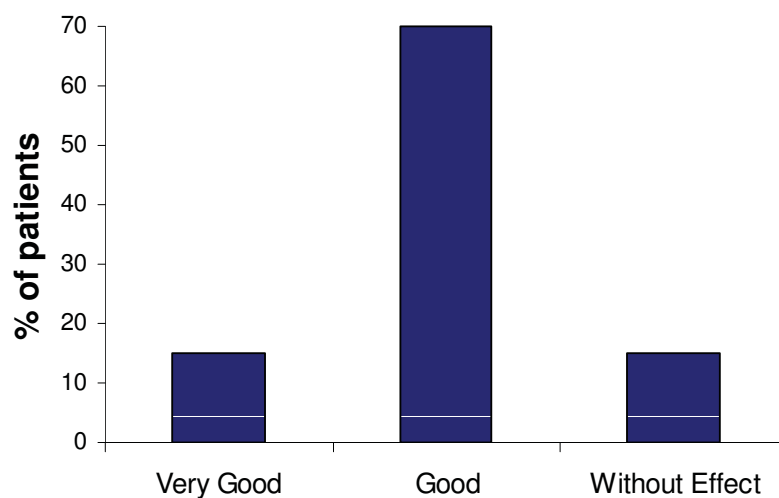
---

## Melaclear Efficacy and tolerance

---

### RESULTS AND DISCUSSION

The photographs of the 20 patients included in this study revealed improvement of the hyperpigmented areas for 17 patients (85%) (Figure 1). MelaClear is able to achieve a decrease in intensity and in the surface of the treated zones. This occurs for all etiologies.



As for safety, there was no serious side effect. The reported adverse effects were one desquamation, one dryness and one erythema.

Melaclear Intense Depigmenting Care has proven to be an effective and safe agent in the very challenging therapeutic area of hyperpigmentation treatment. A major part of the success of the product is without any doubt its formulation. The strength of Melaclear formulation comes from the combination of L-Ascorbic Acid concentrated at 10 % with Phytic Acid 2 %. These ingredients act synergistically at four different levels to block the cascade of reactions leading to the formation of melanin. L-Ascorbic acid in Melaclear formula also decreases the melanocyte dendricity after melanin synthesis. Melaclear therefore ensures a complete blockade of melanin synthesis by interfering during the three phases of the pigment formation.

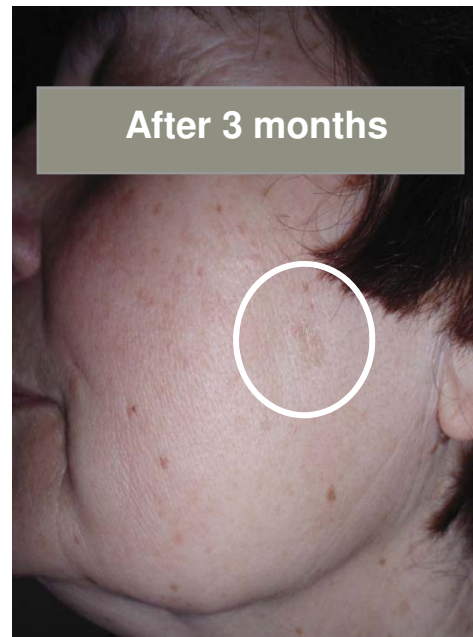
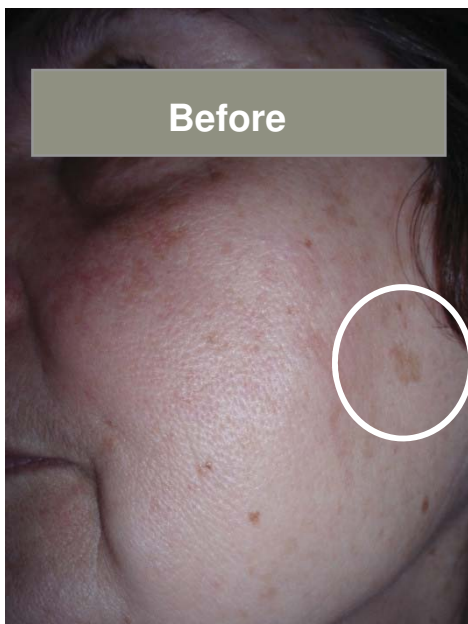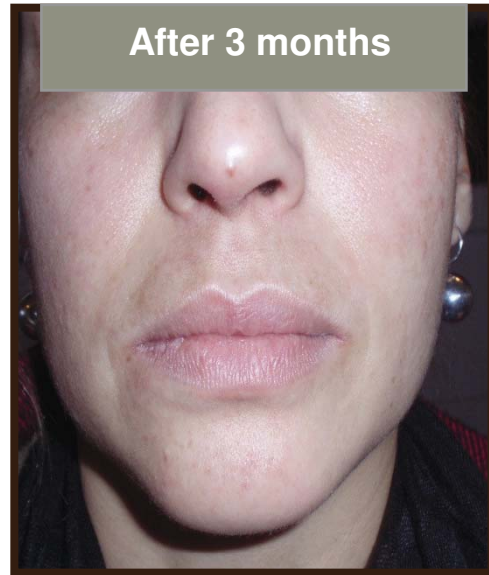
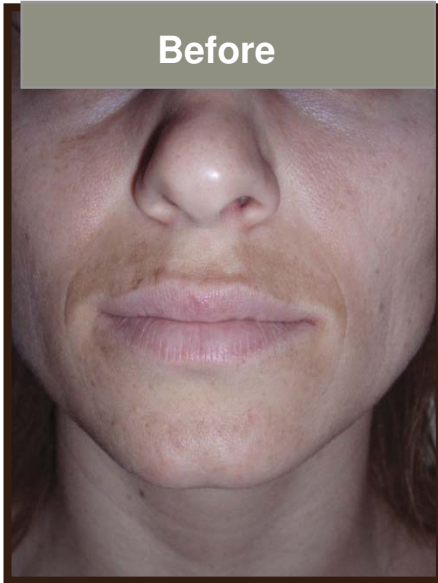
---

## Melaclear Efficacy and tolerance

---

### RESULTS AND DISCUSSION

Several clinical cases are presented in the following pictures.



**Comparative study of Melaclear versus  
Hydroquinone 4 % in the treatment of  
hyperpigmentation : A double blind randomized trial on  
efficacy, biometry, tolerance and sensoriality.**

Dr I. Karavani, Dermatologist, Carpe Clinic, Antwerp, Belgium, 2007



## **Melaclear versus Hydroquinone 4 %**

---

### **INTRODUCTION**

Photodamage is characterized by prematurely aged skin from the deleterious effects of acute and chronic ultraviolet light exposure. Clinical features of photodamage include coarse and fine wrinkling, mottled pigmentary changes, lentigines, sallowness and telangectasias. Treating disorders of pigmentation can prove challenging. Medical therapies include broad-spectrum sunscreens, Hydroquinone, Tretinoin, Tazarotene, Retinol, Kojic Acid, Licorice, Azelaic Acid, Alpha Hydroxyl Acids, Salicylic Acid. However, the mainstay for treating these conditions is most often hydroquinone, which inhibits the conversion of dopa to melanin by interfering with the enzyme tyrosinase. Dermatologists can use varying concentrations depending on the severity of the condition being treated. Although for most of the specialists, Hydroquinone is still the golden standard to treat hyperpigmentation, they all recognize that tachyphylaxis occurs after a few weeks. New alternatives exerting both potency and safety need to be developed.

### **OBJECTIVES**

The aim of the study was to compare the effectiveness of Melaclear to a formulation containing 4 % of Hydroquinone. The primary objective was the evaluation of the effect on skin pigmentation: both the area and the intensity of the pigmentary zone were investigated. The secondary objectives were the assessment of the tolerance and the evolution of skin structure during the treatment course.

### **PATIENTS AND METHODS**

6 patients with diagnosed hyperpigmentation (lentigines, melasma) following an overexposure to the sun were enrolled. These patients had Fitzpatrick skin types V. Patients were followed during a period of 3 months and evaluations were performed at discharge, after 4 weeks, 9 weeks and 13 weeks. This study was a double blind, randomized trial: each side of the face was randomly assigned to one of the products. Ultraviolet photographs were taken at each visit to visualize the distribution of the pigment in the skin layers. The regression of the pigmentary areas was quantified with the Skin Evidence System. The evaluation of the tolerance and the modifications of skin structures were also performed with this multifunctional device.

## Melaclear versus Hydroquinone 4 %

---

### RESULTS AND DISCUSSION

The UV photographs of the 6 patients included in this study revealed improvement of the hyperpigmented areas. Both formulations were able to achieve a decrease in intensity and in the surface of the treated zones. There were no differences in overall global improvement either, suggesting that these products were comparable in efficacy. Melaclear was therefore at least equivalent to Hydroquinone 4 %. This effect is entirely due to the active ingredients, both formulations having the same excipients. For some of the patients, the global evaluation trend showed a superiority of Melaclear Intense Depigmenting Care. According to the new classification of lightening agents developed by Briganti S. and al (1), Hydroquinone and Melaclear are both acting during the melanin synthesis phase. The limiting factor in Hydroquinone therapies arises from the fact that the target of the molecule is only the tyrosinase (interaction with coppers at the active site, inhibition of DNA or RNA synthesis). With the active components present in Melaclear formulation, several intermediates in melanin synthesis that are sensitive to redox properties are inhibited (DHI, DHICA, Cysteinyl-dopa). This could lead to a more complete blockade of the chain reactions involved in melanogenesis.

On the other hand, as we can see from the figure 2, treatments with Hydroquinone 4 % showed pronounced erythema. While the tolerance was excellent with Melaclear. this could, among others, be explained by the presence of the ROS Modulator System made of powerful anti oxidants.

Many specialists need to incorporate resurfacing procedures and therefore use chemical peels, microdermabrasion, IPL. But, in darker skin patients, these procedures are often increasing the likelihood of developing PIH. This study has put into evidence the resurfacing properties of the new depigmenting agent. Men should consider this as an interesting opportunity to have the control of the skin's patient in its globality.

## Melaclear versus Hydroquinone 4 %

Figure 1: UV photographs showing the patient at discharge (left) and after 13 weeks of therapy

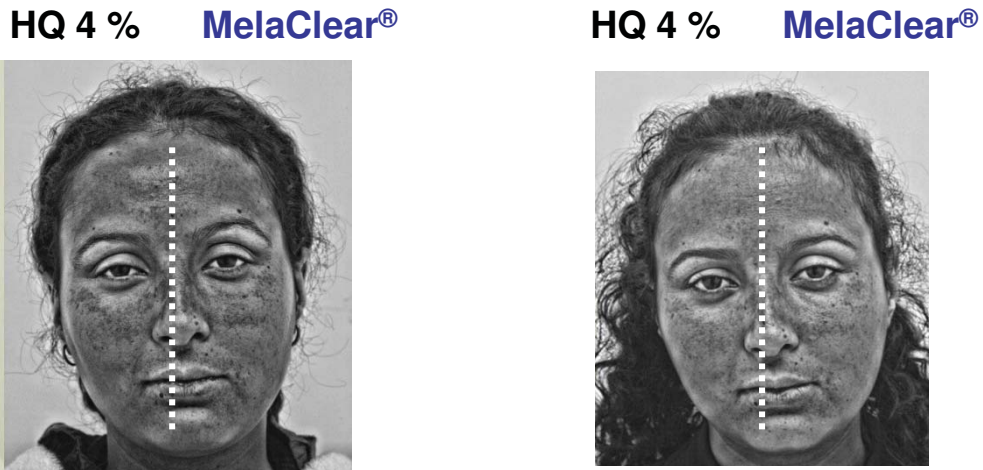




Figure 2: degree of erythema during the treatment with Melaclear (left) and Hydroquinone (right)

### MelaClear®

Number of spots : 0.00		
Used surface : 0.00 mm <sup>2</sup>		
Spots characteristics :	Surface :	Pigmentation :
		
Hyperpigmentation spot(s)		

### Hydroquinone

Number of spots : 0.00		
Used surface : 0.00 mm <sup>2</sup>		
Spots characteristics :	Surface :	Pigmentation :
		
Hyperpigmentation spot(s)		

## CONCLUSION

The results exposed previously could constitute an open window to alternative treatments not involving Hydroquinone. A fair demand exists for therapies that could prove long term efficacy and safety. Melaclear appears to combine these two requests that are fundamental in the treatment of pigmentary disorders. This agent compounds a high level of comfort during the use, a total absence of side effects and an improved effectiveness compared to existing options.

---

## Melaclear versus Hydroquinone 4 %

---

### BIBLIOGRAPHY

- (1) Briganti S, Camera E, Picardo M. *Chemical and Instrumental Approaches to treat Hyperpigmentation*. Pigment Cell Res. 2003; 16: 101-110.
- (2) Ros JR, Rodriguez-Lopez N, Garcia-Canovas F. *Effect of L-ascorbic acid on the monophenolase activity of tyrosinase*. Biochem J. 1993; 295: 309-312.
- (3) Régnier M, Tremblay C, Schmidt R. *Vitamin C affects melanocyte dendricity via keratinocytes*. Pigment Cell Research 18 (5), 389–390.
- (4) Stulberg DL, Clark N. *Common Hyperpigmentation Disorders in Adults : Part I. Diagnostic Approach, Café au Lait Macules, Diffuse Hyperpigmentation, Sun Exposure and Phototoxic Reactions*. Utah Valley Family Practice Residency Program, Provo, Utah, 2003 Nov.
- (5) Stulberg DL, Clark N. *Common Hyperpigmentation Disorders in Adults : Part II. Melanoma, Seborrheic Keratoses, Acanthosis Nigricans, Melasma, Diabetic Dermopathy, Tinea Versicolor and Postinflammatory Hyperpigmentation*. Utah Valley Family Practice Residency Program, Provo, Utah, 2003 Nov.
- (6) James AJ, Tabibian MP, Ditre CM. *Skin Lightening and Depigmenting Agents*. Department of Dermatology, University of Pennsylvania Medical Center, Pennsylvania, 2006 June.
- (7) Halder RM, Richards GM. *Topical Agents Used in the Management of Hyperpigmentation*. Division of Dermatology, Faculty of Medicine, University of British Columbia, Vancouver, British Columbia, Canada, 2004 July.